


Journal Pre-proof

COVID-19 and ENT Pediatric otolaryngology during the COVID-19 pandemic. Guidelines of the French Association of Pediatric Otorhinolaryngology (AFOP) and French Society of Otorhinolaryngology (SFORL)



N Leboulanger T Sagardoy M Akkari S Ayari-Khalfallah C Celerier P Fayoux R Luscan A L Mansbach E Moreddu S Pondaven F Simon N Teissier B Thierry A Fanoux E Lescanne R Nicollas V Couloigner

PII: S1879-7296(20)30100-9

DOI: <https://doi.org/doi:10.1016/j.anorl.2020.04.010>

Reference: ANORL 1053

To appear in: *European Annals of Otorhinolaryngology, Head and Neck diseases*

Please cite this article as: Leboulanger N, Sagardoy T, Akkari M, Ayari-Khalfallah S, Celerier C, Fayoux P, Luscan R, Mansbach AL, Moreddu E, Pondaven S, Simon F, Teissier N, Thierry B, Fanoux A, Lescanne E, Nicollas R, Couloigner V, COVID-19 and ENT Pediatric otolaryngology during the COVID-19 pandemic. Guidelines of the French Association of Pediatric Otorhinolaryngology (AFOP) and French Society of Otorhinolaryngology (SFORL), *European Annals of Otorhinolaryngology, Head and Neck diseases* (2020), doi: <https://doi.org/10.1016/j.anorl.2020.04.010>

This is a PDF file of an article that has undergone enhancements after acceptance, such as the addition of a cover page and metadata, and formatting for readability, but it is not yet the definitive version of record. This version will undergo additional copyediting, typesetting and review before it is published in its final form, but we are providing this version to give early visibility of the article. Please note that, during the production process, errors may be discovered which could affect the content, and all legal disclaimers that apply to the journal pertain.

© 2020 Published by Elsevier.

**COVID-19 and ENT Pediatric otolaryngology during the COVID-19 pandemic.
Guidelines of the French Association of Pediatric Otorhinolaryngology (AFOP) and
French Society of Otorhinolaryngology (SFORL)**

N. Leboulanger^{a,*}, T. Sagardoy^b, M. Akkari^c, S. Ayari-Khalfallah^d, C. Celerier^a, P. Fayoux^e, R. Luscan^a, A.-L. Mansbach^f, E. Moreddu^g, S. Pondaven^h, F. Simon^a, N. Teissierⁱ, B. Thierry^a, A. Fanoux^j, E. Lescanne^h, R. Nicollas^g, V. Couloigner^a

French Association of Pediatric Otorhinolaryngology (AFOP)

French Society of Otorhinolaryngology, Head and Neck Surgery (SFORL)

^a Service d'ORL Pédiatrique et de Chirurgie Cervico-Faciale, Hôpital Necker-Enfants Malades, Assistance Publique – Hôpitaux de Paris, Université de Paris, Paris, France

^b Service d'ORL Pédiatrique et de Chirurgie Cervico-Faciale, Hôpital Pellegrin, Université de Bordeaux, Bordeaux, France

^c Service d'ORL Pédiatrique et de Chirurgie Cervico-Faciale, Hôpital Gui de Chauliac, CHU de Montpellier, Université de Montpellier, France

^d Service d'ORL Pédiatrique et de Chirurgie Cervico-Faciale, Hôpital Femme, Mère, Enfant, Hospices Civils de Lyon, Université Claude Bernard Lyon 1, Lyon, France

^e Service d'ORL Pédiatrique et de Chirurgie Cervico-Faciale, Hôpital Jeanne de Flandre, CHRU Lille, France

^f Service d'ORL Pédiatrique et de Chirurgie Cervico-Faciale, Hôpital Universitaire des Enfants Reine Fabiola (HUDERF), Bruxelles, Belgique

^g Service d'ORL Pédiatrique et de Chirurgie Cervico-Faciale, Hôpital La Timone, Assistance Publique – Hôpitaux de Marseille, Aix-Marseille Université, Marseille, France

^h Service d'ORL Pédiatrique et de Chirurgie Cervico-Faciale, CHU Tours, Université de Tours, Tours, France

ⁱ Service d'ORL Pédiatrique et de Chirurgie Cervico-Faciale, Hôpital Robert Debré, Assistance Publique – Hôpitaux de Paris, Université de Paris, NeuroDiderot, Inserm, F-75019, Paris, France

^j Service d'ORL Pédiatrique et de Chirurgie Cervico-Faciale, Université McGill, Montréal, Québec, Canada

* Corresponding author.

Email address: nicolas.leboulanger@aphp.fr (N. Leboulanger)

Département d'ORL et chirurgie cervico-faciale pédiatrique, Hôpital Necker-Enfants Malades, APHP, 149 rue de Sèvres, 75015 Paris, France

Journal Pre-proof

ABSTRACT

Objective: joint guidelines of the French Pediatric Otolaryngology Society (AFOP) and of the French Society of otorhinolaryngology – Head and neck Surgery (SFORL) on the management of paediatric otolaryngology patients in the context of the COVID-19 pandemic.

Methods: A nation-wide workgroup drew guidelines based on clinical experience, national and local recommendations and scientific literature. Proposals may have to be updated on a day-to-day basis.

Results: In children, incidence of symptomatic COVID-19 (1-5%) is low and of good prognosis. The indications for nasal flexible endoscopy should be drastically limited. If undertaken, full Personal Protective Equipment (PPE) including FFP2 masks are required, as well as use of a sheath. Saline nose wash done by caregivers other than parents at home should require PPE. Unless foreign body tracheobronchial aspiration is clinically obvious, CT-scan should be performed to confirm indication of endoscopy. Surgical indications should be limited to emergencies and to cases that cannot be delayed beyond 2 months (especially endonasal, endopharyngeal laryngo-tracheobronchial procedures). Postponement should ideally be a group decision and recorded as such in the medical file. Surgical techniques should be adapted to limit the risk of viral dissemination in the air, avoiding the use of drills, microdebriders, monopolar cautery or lasers. Continuous suction should be placed near the operating field. In case of confirmed Covid-19 cases, or suspected cases (or in some centres systematically), PPE with FFP2 mask should be worn by all staff members present in the operating room.

Keywords: Paediatric

ENT

Otolaryngology

COVID-19

SARS-CoV-2

Coronavirus

Pandemic

Journal Pre-proof

Introduction

The authors hereby present the joint guidelines of the French Paediatric Otolaryngology Society (Association Française d'ORL Pédiatrique – AFOP, www.afop.fr) and of the French Society of Otorhinolaryngology – Head and neck Surgery (Société Française d'Oto-Rhino-Laryngologie et de Chirurgie de la Face et du Cou – SFORL, www.sforl.org) on the management of paediatric otolaryngology patients in the context of the COVID-19 pandemic. In this document, Covid+ is used to refer to patients infected by SARS-CoV-2.

Materials and Methods

A nation-wide work group was entrusted with a review of the scientific literature on the above topic. Guidelines were drawn up, based on clinical experience, nation-wide or local recommendations, those of other scientific societies and clinical studies in progress. Given the rapid evolution of the worldwide pandemic, and the daily updates in the scientific literature, the following proposals may have to be updated on a day-to-day basis.

Results

1. Specifics concerning SARS-CoV-2 in children

An update on this subject written by INFOVAC-FRANCE is available at the following address: <https://www.infovac.fr/actualites/bulletin-supplementaire-22-mars-2020-mise-au-point-sur-le-covid-19-en-pediatrie>

1.1 Prevalence of SARS-CoV-2 infection in the child

Cases are much rarer than in adults. In a Chinese series of 44,672 confirmed cases, only 2% of patients were under 19 years of age and 0.9% under 10 years of age [1]. In a Korean series, 4.8% of patients were under 19 years of age and among them, only 15.9% under the age of 9 [2]. In Italy, out of 22,000 confirmed cases, 1.2% of patients were younger than 18 [3]. And, in the United States, out of 4000 confirmed cases, only 5% are children [4].

The infection may occur at any age, the median age reported is 7 years [5–7].

1.2 Transmission/contagiousness

As in adults, direct, human-to-human transmission is the result of the projection of droplets, by hand contact or via an inert surface. The virus is viable for up to several days depending on surfaces (plastic 72 hours and stainless steel 48 hours): young children tend to touch everything and it is advisable to regularly disinfect all surfaces in offices and consultation rooms, as well as hospital rooms for children. Conventional disinfection methods are effective [8].

Stools are potentially contaminating: young children do not have the same hygienic reflexes as an adult, thus it is recommended to clean all the surfaces having potentially been in contact with a contaminated child (bowl rim, flush button, door handle, etc.) after toilet use. Although viral RNA has been found in the stool, no oro-fecal transmission has yet been documented [9,10].

No case has been described of maternal-fetal transmission of the virus in pregnant women infected with SARS-CoV-2 [11,12].

Incubation time in children varies from 2 to 10 days [13]. Concerning, the duration of contagiousness, there is no specific paediatric data. In adults, the median duration of presence of viral RNA in upper respiratory secretions is 10.5 days (6-12 days) [14] and it is usual practice to quarantine subjects for 15 days. The same attitude is thus recommended in a Covid-19 + child.

1.3 Symptoms, prognosis, diagnostic tests

The suggestive symptoms are the following: fever, dry cough, headache, myalgia, digestive disorders, acute anosmia without nasal obstruction, acute dysgeusia, but also infectious ENT complications such as mastoiditis, rhino-sinusitis, cervical or peripharyngeal collections. Unilateral facial paralysis might also be an associated sign. It is recommended, even in the

COVID-19 pandemic context, to treat severe forms of acute facial paralysis (grades 5 or 6 of the House - Brackmann classification) with short-term oral corticosteroid therapy (5 to 7 days) (see up-to-date dedicated recommendations “Corticothérapie en ORL” on the SFORL website <https://www.sforl.org/actualites-covid-19/>).

According to the Chinese paediatric series [5], prognosis is good since 90% of children were asymptomatic or paucisymptomatic, 5.2% with oxygen desaturation and only 0.6% with acute respiratory distress. However, younger children appear to be the most likely to develop severe forms. The prevalence of the most severe forms was 10.6% for children of less than 1 year Covid + in the same series [5]. The earliest symptomatic case reported is that of a 55-day-old child [15].

Covid infection in children seems to have a good prognosis: no deaths of children have been reported in Italy or China [3,5,6,16].

- **Diagnosis:**

The usual lab workups can show biological abnormalities such as lymphopenia and elevated CRP. Concerning the sensitivity of RT-PCR on nasopharyngeal samples, there is no specific paediatric data , but it has been shown to be 60% in adults [17,18].

The chest CT-scan, however, has a sensitivity of over 90%, the first lesions appearing being pulmonary nodules [18]. The CT-scan was abnormal for all severe forms of SARS-CoV-2 infections in children [19].

2. Precautions in the clinic

2.1 Indications

They are limited to the following cases:

- Emergencies
- Mandatory clinical examination in order to offer proper medical or surgical management
- Indispensable post-operative care

Ideally, a dedicated space should be reserved to perform the procedure, with as little material as possible to facilitate cleaning between each exam (see up-to-date dedicated recommendations “Rôle du spécialiste ORL dans la situation de crise induite par la pandémie de COVID-19” on the SFORL website <https://www.sforl.org/actualites-covid-19/>).

2.2 Flexible nasal endoscopy

The flexible nasal endoscopy should be limited to restricted indications because at high risk of viral dissemination in the air [14]. Endoscopy should not be performed otherwise, in particular not for airway obstruction diagnosis if it is clinically well tolerated.

It should be performed in the following conditions:

- Otolaryngologists should wear full Personal Protective Equipment (PPE): FFP2 mask, overcoat, cap, protective glasses. All of this equipment is then thrown into dedicated infected waste bins in the examination room except for the protection glasses that can be decontaminated and reused.
- The nasal endoscope is placed on a clearly separate table; if used, the camera should have a protective cover.
- A sheath should be used. After removal, thorough cleansing of the entire endoscope, including the proximal areas that have not been in direct contact with the nasal cavity should be performed. An alternative to the use of sheaths is the decontamination of the endoscope after each use, following the usual decontamination procedures.

- Thorough cleaning of all surface areas of the examination room.
- A delay of at least 30 min should be given before reusing this room for another patient.
- Local anaesthesia with lidocaine spray is not recommended.

The following link leads to a document explaining in detail PPE precautions:

<https://www.openpediatrics.org/assets/document/donning-and-doffing-personal-protective-equipment-high-resolution-color>

3. Newborn hearing screening

Newborn hearing screening is authorized if practiced by staff not working directly with COVID patients and if the mother is asymptomatic. The protection of the tester should include: surgical mask, surgical hand scrubs before and after each test; the gloves should be taken off after each test. The equipment should be decontaminated after use.

Special care should be taken not to lose track of children who have to be retested after discharge from maternity (lists of children who have to be tested again after the crisis is over should be established)

4. Medical treatment

- Saline nasal irrigation:

Saline nasal irrigation should be limited to decreasing nasal blockage, especially in infants. The following precautions should be taken:

- No particular precaution should be taken at home because, even in the absence nasal irrigation, an infected child has a high risk of contaminating his siblings and his parents.
- In the hospital, the risk is to contaminate staff caregiver, therefore precautions should be implemented in this context: wearing a surgical mask, gloves, goggles, a gown

- Corticosteroids:

The prescription of corticosteroid therapy in otolaryngology is mentioned in two other SFORL documents (see up-to-date dedicated recommendations “Corticothérapie en ORL” and “Consultations et traitements médicamenteux en rhinology en context d’épidémie Covid-19” on the SFORL website <https://www.sforl.org/actualites-covid-19/>).

- A short steroid therapy can be prescribed to treat severe forms of acute facial paralysis (grades 5 and 6 of the House Brackmann classification) and sudden sensorineural hearing loss (greater than 60 dB).

- The use of steroids for polyposis, infectious sinusitis and anosmia is not recommended.

5. Paediatric otolaryngology surgical procedures

5.1 Indications

Procedures that cannot be postponed for more than 2 months and for which there is no medical therapeutic alternative are the only ones that should be maintained during the pandemic. In difficult cases (ie: cholesteatoma, tonsil hypertrophy with severe OSAS), it should ideally be discussed collectively with a written decision recorded in the medical file. For patients managed in private practice, it is possible to seek advice from the Ethics Committee of the Professional ENT National Council (ceorl@sforl.org).

- Tonsillectomy or adenoidectomy in severe OSA:

Indications should to be limited as much as possible, as the salivary secretions, the nasopharynx and probably the tonsil tissues (virus tropism for lymphocytes) have a high viral load. In case of urgent therapeutic indication, tonsillectomy should be preferred to non-invasive ventilation, the latter being at high risk for viral dissemination in the ambient air and requiring a hospital bed, often in ICU, for several days

In the absence of data on the subject, it is not recommended to use any particular tonsillectomy technique.

- Endonasal surgery:

Indications should be strictly limited because of the high viral load present in the nasal cavities and the risk of dissemination of viral particles in the ambient air. Surgeries such as bilateral choanal atresia and poorly tolerated congenital piriform aperture stenosis despite optimal medical treatment can be maintained.

- Tympanic ventilation tubes

The theoretical presence of the virus in the otitis effusion is not yet documented. However, the procedure should not be maintained during the epidemic period as it is considered non-urgent.

- Tympanoplasties for retraction pockets and cholesteatomas

Indications should be discussed on a case-by-case basis depending on the extensions and possible complications: meningeal exposure, labyrinthine fistula, facial paralysis. Postponement is possible in the vast majority of cases.

- Airway endoscopies for suspected foreign bodies aspiration. Three situations can be considered:

- The foreign body is clinically very strongly suspected (parents have witnessed the aspiration of a foreign body, there is a clear aspiration syndrome, persistent cough, dyspnea): the indication for tracheobronchial endoscopy should be maintained without prior CT-scan.

- Doubt is cast on foreign body aspiration (aspiration syndrome without subsequent clinical anomaly, or conversely clinical compatible (cough, choking, dyspnea, asymmetric auscultatory abnormalities), but without frank aspiration syndrome or any other obvious aetiology): chest

CT-scan is recommended, after which, tracheobronchial endoscopy is performed if the CT-scan reinforces suspicion (visualisation of the foreign body; unilateral expiratory trapping; systematized ventilation anomalies); the radiologist may then also check the CT-scan for pneumological signs in favour of a Covid-19.

- In a case with very little suspicion (no frank aspiration syndrome, no suggestive clinical anomalies), no CT-scan nor tracheobronchial endoscopy is recommended.

• Other indications for airway or oesophagus endoscopy should be maintained:

- Button battery ingestion (oesophagus, nasal cavity)

- Caustic ingestion

- Repeated extubation failure, after discussion with neonatologists or intensive care anaesthetist

• Tracheostomy

Very few indications should be maintained, and should be discussed on a case-by-case basis due to a high risk of dissemination of viral particles during the procedure and also subsequently during tracheostomy tube changes

• ENT oncological surgery

Few indications exist (see up-to-date dedicated recommendations “Cancérologie ORL et Covid-19: Etat des lieux” on the SFORL website <https://www.sforl.org/actualites-covid-19/>).

• Mastoiditis, complicated sinusitis, cervical or peripharyngeal abscess

Exclusive medical treatment based on intravenous antibiotic therapy guided by bacteriological samples should be preferred. Pus should be sampled using nitrous oxide (retro-auricular abscesses in cases of mastoiditis, cervical collections). In case of surgery, prefer external

approaches to endoscopic procedures when possible (e.g. frontal sinus external drainage procedure or Lynch approach for ethmoiditis).

5.2 Preoperative workup to test for COVID-19

The nasopharyngeal swab with RT-PCR performed within 48 hours preoperatively, unfortunately demonstrates 30 to 40% of false negative. It is, however, always useful. It becomes necessary if suggestive signs of Covid-19 infection are present (see paragraph 1.3)

Urgent procedures should not be delayed by the expectancy of the results such as severe or progressive dyspnea, haemorrhages or severe infections

The sensitivity of thoracic CT-scan is above 90% (see paragraph 1.3). If a CT-scan is required in the usual preoperative assessment (mastoiditis, complicated sinusitis, cervical or peripharyngeal abscess, tumours), a complementary chest CT-scan must systematically be done. In other situations, discussion should be made on a case-by-case basis according to age, symptoms and CT-scan availability.

In case of preoperative diagnosis of Covid-19 infection, non-urgent surgeries should be postponed for at least 15 days (usual duration of quarantine in infected subjects)

5.3 Surgical caution

Systematic precautions should be taken for whichever procedure and whatever the patient Covid-19 status.

- The number of operators in the operating theatre should be kept minimal and particularly close to the child's head.
- Protective goggles should be worn due to the risk of splashes of contaminated biological liquids; these goggles must be decontaminated afterwards.

- Procedure should be done as fast as possible and performed by an experienced senior surgeon.
- The masks should be systematically worn, depending on the endowments of the centres, either FFP2 for all indications (attitude taking into account the high percentages of asymptomatic children and false negative PCR) or use of FFP2 restricted to specific cases, according to symptoms, COVID status and type of surgery (see below).

In case of confirmed or suspected Covid-19 + patients (fever, cough, pharyngitis, myalgia, headache, anosmia, sinusitis, mastoiditis, phlegmon), FFP2 mask should be worn by all staff members present in the operating theatre.

Additional specific precautions should be taken during procedures involving the airways, regardless of the patient's Covid-19 status such intubations / extubations, endoscopy, endonasal surgeries, adenoidectomies / tonsillectomies, but also by extension middle ear surgeries since the latter is lined with respiratory mucosa.

- The FFP2 mask should then be worn for all staff members present in the operating theatre.
- If possible, the procedure should be performed in negative pressure operating rooms, with air filtration/purification system; this should be discussed with the medical officer of health care structure.
- Techniques favouring the suspension of infected tissue micro-fragments should be avoided as much as possible: drilling, microdebrider and possibly also monopolar electrosurgical unit, laser, radiofrequency tip, coblation probe, microdebrider blade.
- When possible, continuous suction should be placed near the field operative.

- For certain procedures, in order to limit virus-loaded liquid splashes, specific surgical setup can be considered in addition to the usual draping based on the use of a flexible hoop and transparent sterile drapes (*Fig. 1a and 1b*).

Disclosure of interest

The authors declare that they have no competing interest.

Acknowledgments

The authors thank Dr. N. Morel, President of the SNORL, and Dr. J.M. Klein, President of the ENT National Professional Council, for exchanges that led to the formulation of these good practice guidelines.

References

- [1] Novel Coronavirus Pneumonia Emergency Response Epidemiology Team. [The epidemiological characteristics of an outbreak of 2019 novel coronavirus diseases (COVID-19) in China]. *Zhonghua Liu Xing Bing Xue Za Zhi*. 2020;41:145–51. doi.org/10.3760/cma.j.issn.0254-6450.2020.02.003.
- [2] Korean Society of Infectious Diseases KS of I, Korean Society of Pediatric Infectious Diseases KS of PI, Korean Society of Epidemiology KS of, Korean Society for Antimicrobial Therapy KS for A, Korean Society for Healthcare-associated Infection Control and Prevention KS for HIC and, Korea Centers for Disease Control and Prevention KC for DC and. Report on the Epidemiological Features of Coronavirus Disease 2019 (COVID-19) Outbreak in the Republic of Korea from January 19 to March 2, 2020. *J Korean Med Sci* 2020; 35:e112. doi.org/10.3346/jkms.2020.35.e112.
- [3] Livingston E, Bucher K. Coronavirus Disease 2019 (COVID-19) in Italy. *JAMA* 2020. doi.org/10.1001/jama.2020.4344.
- [4] Bialek S, Boundy E, Bowen V, Chow N, Cohn A, Dowling N, et al. Severe Outcomes Among Patients with Coronavirus Disease 2019 (COVID-19) — United States, February 12–March 16, 2020. *MMWR Morb Mortal Wkly Rep* 2020;69:343–6. doi.org/10.15585/mmwr.mm6912e2.
- [5] Dong Y, Mo X, Hu Y, Qi X, Jiang F, Jiang Z, et al. Epidemiological Characteristics of 2143 Pediatric Patients With 2019 Coronavirus Disease in China. *Pediatrics* 2020. doi.org/10.1542/peds.2020-0702.
- [6] Lu X, Zhang L, Du H, Zhang J, Li YY, Qu J, et al. Chinese Pediatric Novel Coronavirus Study Team, SARS-CoV-2 Infection in Children. *N Engl J Med* 2020.

- doi.org/10.1056/NEJMc2005073.
- [7] Wei M, Yuan J, Liu Y, Fu T, Yu X, Zhang Z-J. Novel Coronavirus Infection in Hospitalized Infants Under 1 Year of Age in China. *JAMA* 2020. doi.org/10.1001/jama.2020.2131.
- [8] Ong SWX, Tan YK, Chia PY, Lee TH, Ng OT, Wong MSY, et al. Air, Surface Environmental, and Personal Protective Equipment Contamination by Severe Acute Respiratory Syndrome Coronavirus 2 (SARS-CoV-2) From a Symptomatic Patient. *JAMA* 2020. doi.org/10.1001/jama.2020.3227.
- [9] World Health Organization. Report of the WHO-China Joint Mission on Coronavirus Disease 2019 (COVID-19) 16-24 february 2020. 2020.
- [10] Yeo C, Kaushal S, Yeo D. Enteric involvement of coronaviruses: is faecal-oral transmission of SARS-CoV-2 possible? *Lancet Gastroenterol Hepatol* 2020;5: 335-7.
- [11] Schwartz DA. An Analysis of 38 Pregnant Women with COVID-19, Their Newborn Infants, and Maternal-Fetal Transmission of SARS-CoV-2: Maternal Coronavirus Infections and Pregnancy Outcomes. *Arch Pathol Lab Med* 2020. doi.org/10.5858/arpa.2020-0901-SA.
- [12] Chen H, Guo J, Wang C, Luo F, Yu X, Zhang W, et al. Clinical Characteristics and Intrauterine Vertical Transmission Potential of COVID-19 Infection in Nine Pregnant Women: A Retrospective Review of Medical Records. *Lancet* 2020;395:809–815. doi.org/10.1016/S0140-6736(20)30360-3.
- [13] Cai J, Xu J, Lin D, Yang Z, Xu L, Qu Z, et al. A Case Series of children with 2019 novel coronavirus infection: clinical and epidemiological features. *Clin Infect Dis* 2020. doi.org/10.1093/cid/ciaa198.

- [14] Chang D, Mo G, Yuan X, Tao Y, Peng X, Wang F, et al. Time Kinetics of Viral Clearance and Resolution of Symptoms in Novel Coronavirus Infection. *Am J Respir Crit Care Med* 2020. doi.org/10.1164/rccm.202003-0524LE.
- [15] Cui Y, Tian M, Huang D, Wang X, Huang Y et al. A 55-Day-Old Female Infant infected with COVID 19: presenting with pneumonia, liver injury, and heart damage. *J Infect Dis* 2020. doi.org/10.1093/infdis/jiaa113.
- [16] Onder G, Rezza G, Brusaferro S. Case-Fatality Rate and Characteristics of Patients Dying in Relation to COVID-19 in Italy. *JAMA* 2020. doi.org/10.1001/jama.2020.4683.
- [17] Wang W, Xu Y, Gao R, Lu R, Han K, Wu G, et al. SARS-CoV-2 in Different Types of Clinical Specimens. *JAMA* 2020. doi: 10.1001/jama.2020.3786
- [18] Ai T, Yang Z, Hou H, Zhan C, Chen C, Lv W, et al. Correlation of Chest CT and RT-PCR Testing in Coronavirus Disease 2019 (COVID-19) in China: A Report of 1014 Cases. *Radiology* 2020. doi.org/10.1148/radiol.2020200642.
- [19] Sun D, Li H, Lu X-X, Xiao H, Ren J, Zhang F-R, et al. Clinical features of severe pediatric patients with coronavirus disease 2019 in Wuhan: a single center's observational study. *World J Pediatr* 2020. doi.org/10.1007/s12519-020-00354-4.

Box 1. Key messages

- Recent literature underlines the low incidence of symptomatic paediatric cases (1-5% in international series)
- Most cases are asymptomatic or paucisymptomatic; exceptionally, severe cases have been reported, especially in the youngest patients with a usually good prognosis
- Hygienic precautions are particularly important to watch out for in young children, who have not yet acquired acceptable personal hygiene
- Nasal endoscopy requires the same precautions as for adults, in particular: indications should drastically be reduced and practitioner should wear Personal Protective Equipment (PPE) such as a FFP2 mask, an overcoat, goggles, a cap, gloves and use a camera (to increase distance) and if possible an endoscopic sheath. The endoscope should be carefully cleaned entirely after removal of the sheath, as well as the surfaces on which the endoscope has been placed. An alternative to the use of sheaths is the systematic decontamination of the endoscope according to usual procedure after each use.
- Saline nose wash is only indicated to decrease nasal blockage, especially in infants; in which case, no specific precautions are necessary when they are carried out at home by the parents; in the hospital, in order to prevent the contamination of caregivers, it is however advisable to wear full PPE.
- Indications for tracheobronchial endoscopy under general anaesthesia for suspected aspirated foreign bodies should be reduced to clinically obvious cases. In other less obvious situations, the indication should be guided by a CT-scan showing direct or indirect signs in favour of a foreign body.
- Surgical indications should be limited to emergencies and cases that cannot be delayed beyond 2 months. Postponement should ideally be a group decision and recorded as such in the medical

file (possible help from ethics committees, ie French National ENT ethics committee: ceorl@sforl.org).

- Surgical techniques should be adapted to limit the risk of viral dissemination in the air: for endonasal surgery, avoid drills and microdebridors and prefer external approaches to drain orbital abscesses in ethmoiditis; mastoidectomies should be performed without drills, using other instruments (hammer, gouge, curette); a continuous suction should be placed near the operating field; monopolar cautery and laser may also be at increased risk for viral dissemination.

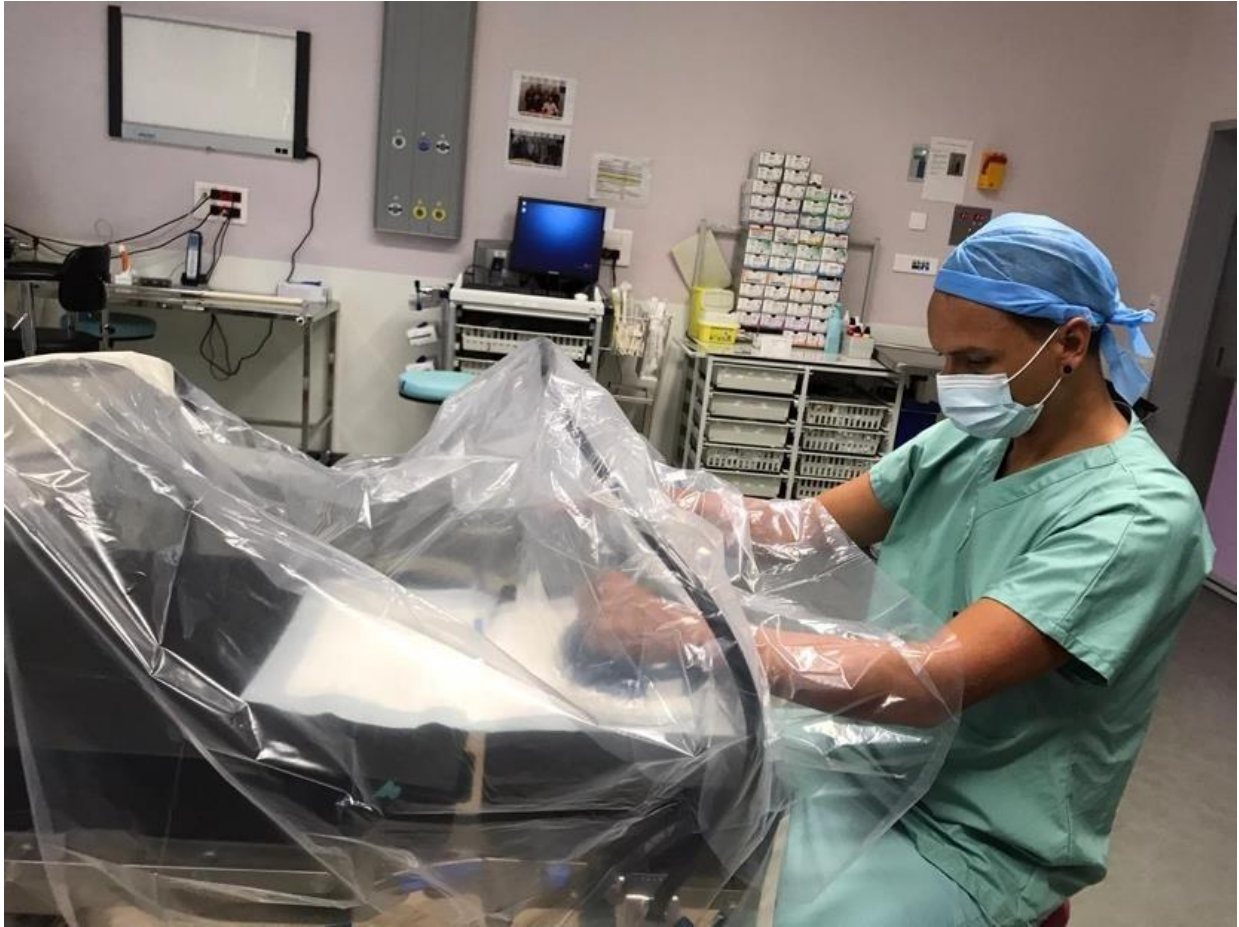- Concerning caregiver protection during surgery, in case of confirmed Covid-19 cases, or in suspected cases (or in some centres systematically), PPE with FFP2 mask should be worn by anybody present in the operating theatre.

Figure 1a and b.

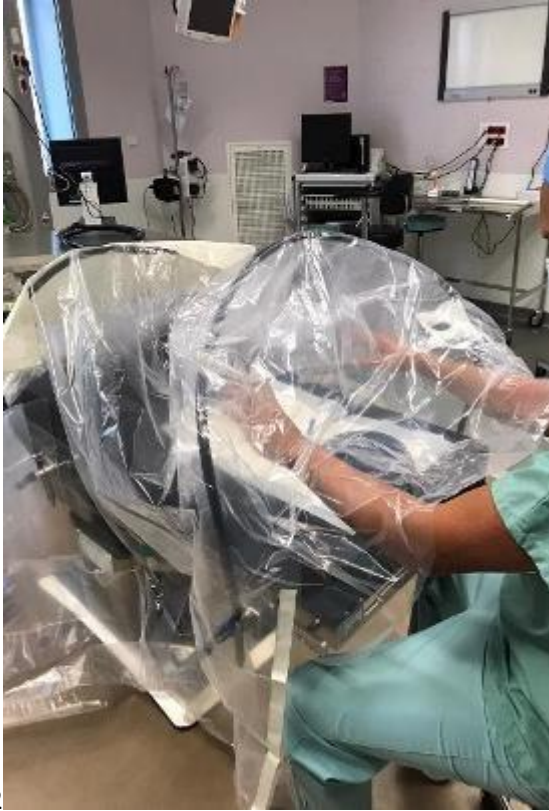Example of setup using a hoop for Boyle-Davis suspension to maintain a surgical transparent sterile drape, thus limiting diffusion in the operating room's atmosphere of suspended tissue microfragments loaded with the virus during certain risky ENT procedures (photo from Pediatric Otolaryngology Department, Necker - Sick Children's Hospital, AP-HP, Paris).

Journal Pre-proof

Figr-1



Journal Pre-proof



Figr-2

Journal Pre-proof